

Case Report



Successful Treatment of Hypothyroidism with Lower-Than-Usual Doses of Levothyroxine Enema in a Patient after Gastric Sleeve Surgery: A Case Report

Mehdi Mohammadi¹, Rana Mojtahedzadeh Larijani², Reza Alizadeh Kashani³, Sholeh Ebrahimpour^{1,2*}

¹Department of Clinical Pharmacy, School of Pharmacy, Alborz University of Medical Sciences, Karaj, Iran

²Pharmaceutical Care Department, Shahid Madani Hospital, Alborz University of Medical Sciences, Karaj, Iran

³Department of Anesthesiology, School of Medicine, Alborz University of Medical Sciences, Karaj, Iran

Received: August 18, 2025, Revised: October 13, 2025, Accepted: October 27, 2025, ePublished: January 5, 2026

Introduction

Primary hypothyroidism is one of the most common endocrine disorders. Hormone replacement therapy is the mainstay of treatment, and the preferred medication is synthetic levothyroxine (LT4), which is usually administered orally. However, the oral route is not available for some patients. LT4 parenteral dosage forms and rectal suppositories are alternatives for these conditions. Unfortunately, these dosage forms are not consistently available.¹

The enteral absorption of LT4 is variable. Although the duodenum and jejunum appear to be the most important sites of absorption, studies have shown that the administration of LT4 via standard jejunostomy tubes can be limited by malabsorption.² This study describes the successful management of hypothyroidism using a small-volume concentrated LT4 enema in a patient who failed to respond to drug administration via a jejunostomy tube (j-tube).

Case Presentation

The patient was a 52-year-old Iranian woman with a medical history of anxiety, morbid obesity (BMI > 40 kg/m²), major depressive disorder, and hypothyroidism. The patient's drug history before admission was as follows: trimipramine 100 mg once daily (OD), lithium 300 mg OD, paroxetine 40 mg OD, bupropion 150 mg OD, and levothyroxine 100 mcg OD. Almost 4 months before admission to our hospital, she underwent gastric sleeve surgery because of morbid obesity. Two days after surgery, a jejunostomy tube (J-tube) was inserted for enteral nutrition. The tube was then obstructed after 4 months, leading to admission to our hospital for jejunostomy tube replacement.

The patient's thyroid function on the day of admission

was normal, as indicated by a total T3=58.8 ng/dL (normal range: 60–181 ng/dL), total T4=2.8 mcg/dL (normal range: 4.6–12 mcg/dL), and TSH=1.93 mIU/L (normal range: 0.55–4.77 mIU/L). Following the insertion of a new J-tube, the patient's hospital stay was prolonged because of leakage from the J-tube and severe sepsis. During the first month of admission, a 100-mcg tablet of levothyroxine was dissolved in 30 mL of water and administered daily via the J-tube. A consultant clinical pharmacist visited the patient to ensure proper administration of LT4 tablets, including at least a 1-hour interval from enteral nutrition and a 4-hour interval from calcium, iron, and multivitamin–multimineral supplements administered during hospitalization. The dose was then increased to 200 mcg when euthyroidism was not achieved, as evidenced by a TSH=25.0 mIU/L on day 29 of hospitalization. At this daily dose, the TSH level increased to 55.8 mIU/L on day 56. Given that parenteral and suppository dosage forms of LT4 were not available, patient consent was obtained for the rectal administration of LT4.

Initially, on day 56 of admission, 2 tablets of LT4 (200 mcg) were ground, dissolved in 30 mL of normal saline (NS), and administered rectally. Owing to the lack of change in the TSH level after 10 days, the daily dose of LT4 increased to 300 mcg. Four days later, laboratory data revealed T3=63.4 ng/dL, T4=6.1 mcg/dL, and TSH=9.64 mIU/L, indicating significant improvement in the patient's condition. On hospital day 73, the TSH level was 2.31 mIU/L, indicating normal thyroid function. During all administrations, the levothyroxine enema was freshly prepared immediately prior to use and was retained for at least 30 minutes. No adverse effects were observed during rectal enema treatment. Figure 1 shows the changes in TSH levels during hospitalization.

*Corresponding Author: Sholeh Ebrahimpour, Email: s.ebrahimpour@abzums.ac.ir

© 2026 The Author(s). This is an open access article and applies the Creative Commons Attribution Non-Commercial License (<http://creativecommons.org/licenses/by-nc/4.0/>). Non-commercial uses of the work are permitted, provided the original work is properly cited.

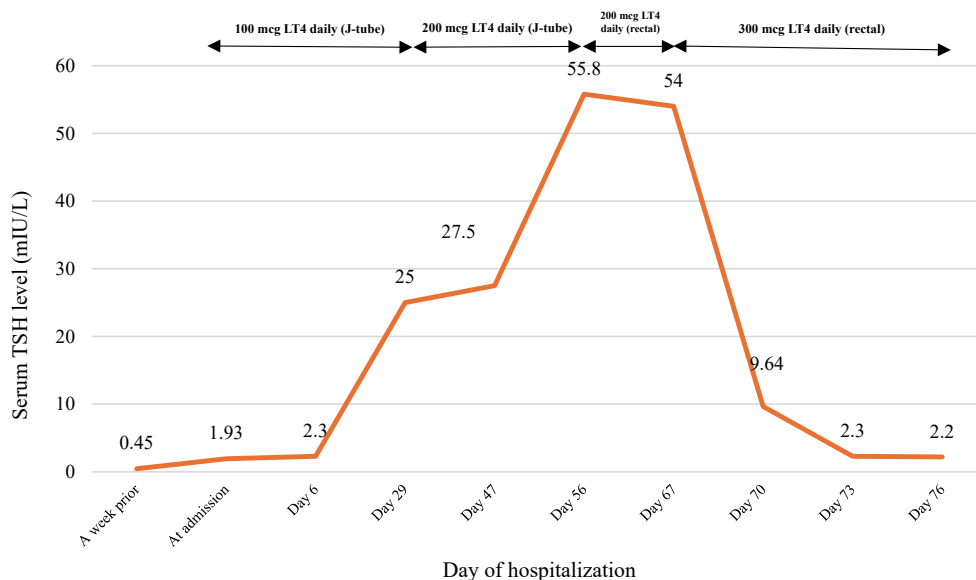


Figure 1. Changes in the TSH levels of the patient during hospitalization

Table 1. An overview of alternative rectal routes for levothyroxine administration in previous studies

Author/year	Sex, age (year)	Route of LT4 administration	LT4 daily dose	LT4 Concentration	Time to desired response
Kashiwagura et al ⁴ , 2014	M, 54	Rectal suppositories	113 mcg (2.2 mcg/kg)	-	-
	M, 61	Rectal suppositories	225 mcg	-	-
	F, 80	Rectal suppositories	300 mcg	-	-
	F, 73	Rectal suppositories	50 mcg (0.92 mcg/kg)	-	-
	F, 86	Rectal suppositories	150 mcg (3.3 mcg/kg)	-	-
	F, 55	Rectal suppositories	125 mcg (2.2 mcg/kg)	-	-
Obeidat et al ¹ , 2018	M, 53	Rectal enema	2000 mcg in 500 ml saline	4 mcg /mL	6 days
Ybarra et al ⁵ , 2018	M, 1	Rectal enema	25 mcg (10 mcg/kg) in 8 ml saline (+ flush)	3.1 mcg /mL	7 days
Tunçel et al ⁶ , 2023	M, 1	Rectal enema	10 mcg/kg	2.5 mcg /mL	9 days
Mak et al ⁷ , 2023	M, 73	Rectal enema	300 mcg (4 mcg/kg) in 10 ml water and 20 ml lidocaine gel	10 mcg /mL	21 days
Peña-González et al ⁸ , 2024	F, 78	Rectal enema	1000 mcg in 300 ml saline	3.3 mcg /mL	21 days
Current study	F, 52	Rectal enema	300 mcg (4.3 mcg/kg)	10 mcg /mL	4 days

LT4: levothyroxine; M: Male; F: Female.

Discussion

Bioavailability is one of the main concerns in J-tube drug administration. Owing to unpredictable absorption, the effect of medications may be decreased or remain unchanged, which necessitates close monitoring of drug effects.³ Although it has been recommended that there is no need to increase the dose of LT4 for enteral administration,³ there are cases of refractoriness to levothyroxine in patients with hypothyroidism and short bowel syndrome, indicating that the duodenum and jejunum are the main absorption sites of LT4.² Our patient also demonstrated that ongoing monitoring of serum T3, T4, and TSH is needed, especially in critically ill patients with prolonged hospitalizations.

In the absence of proper alternatives to oral LT4, the treatment of hypothyroidism can be challenging. Rectal administration of LT4 has been investigated as an

alternative to oral therapy in previous studies. As shown in Table 1, various doses and concentrations of LT4 were used.

In this study, we used 2–3 tablets of LT4 dissolved in 30 ml of saline. A favorable response was observed after 4 days of initiating LT4 enema at a concentration of 10 mcg /mL. Compared with the other patients in Table 1, our patient had the shortest response time, which might be due to several factors affecting drug absorption from the rectum, such as formulation osmolarity, anatomical variations, genetics, and pathophysiological factors.

When a drug is administered as a rectal suppository, it must first be released from the formulation and solubilized in a low volume of rectal fluid; therefore, the formulation plays a key role in rectal absorption of the medication.⁹ As shown in Table 1, the daily doses of LT4 suppositories required to achieve similar effects were

approximately 2–3 times greater than those required for the tablet form. Liquid dosage forms (e.g., enemas) do not require the initial phases of disintegration, liquefaction, and/or dissolution of the formulation to release the drug; therefore, the systemic absorption of enemas can be greater and faster than that of suppositories.⁴ A notable aspect of our study was the preparation of a concentrated rectal enema (10 mcg /mL), which resulted in the rapid correction of thyroid function tests. The administration of rectal enemas larger than 80 mL can stimulate defecation and is associated with a shorter retention time, which may compromise drug absorption.⁹ This may explain the delayed response times of patients who received more diluted enemas.^{5,6,8}

Several nonthyroidal disorders may affect the concentrations of thyroid hormones and TSH in inpatient settings. For example, it has been shown that the concentration of T3 decreases acutely in patients with sepsis, while the serum levels of T4 and TSH remain unchanged.¹⁰ Furthermore, there are no reliable data from clinical studies on the extent of levothyroxine absorption from enemas in patients with sepsis. Although there is controversy regarding which laboratory test is preferable for monitoring thyroid function in inpatient settings, it is recommended that both serum TSH and total/free T4 be monitored in these patients.¹¹ Our patient became euthyroid following the administration of 300 mcg of LT4 enema daily, as evidenced by the normal levels of both TSH and total T4.

In general, our findings are consistent with those of other studies on the effectiveness of LT4 administration via enema. In addition, the relatively high concentration of the LT4 enema in this study may have contributed to the observed rapid response.

Authors' Contribution

Conceptualization: Mehdi Mohammadi, Sholeh Ebrahimpour.

Data curation: Sholeh Ebrahimpour.

Formal analysis: Mehdi Mohammadi, Rana Mojtahedzadeh Larijani, Sholeh Ebrahimpour.

Investigation: Reza Alizadeh Kashani, Sholeh Ebrahimpour.

Methodology: Mehdi Mohammadi, Sholeh Ebrahimpour.

Project administration: Sholeh Ebrahimpour.

Resources: Rana Mojtahedzadeh Larijani.

Supervision: Sholeh Ebrahimpour.

Validation: Reza Alizadeh Kashani.

Visualization: Mehdi Mohammadi.

Writing—original draft: Rana Mojtahedzadeh Larijani.

Writing—review & editing: Mehdi Mohammadi, Reza Alizadeh

Kashani, Sholeh Ebrahimpour.

Competing Interests

The authors declare that they have no conflicts of interest.

Ethical Approval

Written consent was obtained from the patient for the publication of anonymized data. The Research Ethics Committee of Alborz University of Medical Sciences approved the study (approval ID: IR.ABZUMS.REC.1403.257).

References

- Obeidat KA, Saadeh NA, As'ad A, Bakkar S. Successful management of hypothyroidism in gastric outlet obstruction using levothyroxine rectal enemas: a case report. *Am J Case Rep.* 2018;19:903-5. doi: [10.12659/ajcr.909437](https://doi.org/10.12659/ajcr.909437).
- Liu H, Li W, Zhang W, Sun S, Chen C. Levothyroxine: conventional and novel drug delivery formulations. *Endocr Rev.* 2023;44(3):393-416. doi: [10.1210/edrev/bnac030](https://doi.org/10.1210/edrev/bnac030).
- Forsberg J, Bedard E, Mahmoud SH. Bioavailability of orally administered drugs in critically ill patients. *J Pharm Pract.* 2023;36(4):967-79. doi: [10.1177/08971900221100205](https://doi.org/10.1177/08971900221100205).
- Kashiwagura Y, Uchida S, Tanaka S, Watanabe H, Masuzawa M, Sasaki T, et al. Clinical efficacy and pharmacokinetics of levothyroxine suppository in patients with hypothyroidism. *Biol Pharm Bull.* 2014;37(4):666-70. doi: [10.1248/bpb.b13-00998](https://doi.org/10.1248/bpb.b13-00998).
- Ybarra M, Dos Santos TJ, Pinheiro CT, Dichtchekenian V, Damiani D. Rectal levothyroxine for the treatment of hypothyroidism: a case study. *Pediatrics.* 2018;142(2):e20173317. doi: [10.1542/peds.2017-3317](https://doi.org/10.1542/peds.2017-3317).
- Tunçel D, İnce Z, Aygün E, Çoban A. An alternative route of treatment in transient hypothyroxinemia of prematurity: rectal administration of levothyroxine. *J Clin Res Pediatr Endocrinol.* 2023;15(2):220-4. doi: [10.4274/jcrpe.galenos.2021.2021.0153](https://doi.org/10.4274/jcrpe.galenos.2021.2021.0153).
- Mak WW, Ng YS, Goh QC, Krishnan GD, Ng YM, Redzuan SR, et al. Successful treatment of hypothyroidism with rectal levothyroxine: a case report. *J ASEAN Fed Endocr Soc.* 2023;38(S2):60-1. doi: [10.15605/jafes.038.S2.98](https://doi.org/10.15605/jafes.038.S2.98).
- Peña-González R-R, Quiroz-Alvarez J, Sánchez-Paredes J, Juárez-Vanegas J-C, Aguilera-Callejas DE, Segovia A, et al. Thyroxine replacement by colonic route and absorption kinetics: case report. *Int Surg J.* 2024;11(2):251-4. doi: [10.18203/2349-2902.isj20240004](https://doi.org/10.18203/2349-2902.isj20240004).
- Hua S. Physiological and pharmaceutical considerations for rectal drug formulations. *Front Pharmacol.* 2019;10:1196. doi: [10.3389/fphar.2019.01196](https://doi.org/10.3389/fphar.2019.01196).
- Mehdi SF, Qureshi MH, Pervaiz S, Kumari K, Saji E, Shah M, et al. Endocrine and metabolic alterations in response to systemic inflammation and sepsis: a review article. *Mol Med.* 2025;31(1):16. doi: [10.1186/s10020-025-01074-z](https://doi.org/10.1186/s10020-025-01074-z).
- Ross DS. Screening thyroid function tests in an acute-care hospital. *Am J Med.* 1994;96(4):393-4. doi: [10.1016/0002-9343\(94\)90077-9](https://doi.org/10.1016/0002-9343(94)90077-9).