



Research Article

Effects of Carob Fruit Extract on Spermatogenesis, Antioxidant Status, and Apoptosis in Adult Male Mice

Seyed Sadegh Sadat¹, Shabnam Mohammadi^{2,1*} , Ghasem Sazegar¹, Alireza Fazel¹, Alireza Ebrahimzadeh¹, Majid Ghayour Mobarhan³, Farimah Beheshti⁴, Seyedeh Saleh Attari¹, Shima Tavallaei³

¹Department of Anatomy and Cell Biology, School of Medicine, Mashhad University of Medical Sciences, Mashhad, Iran.

²Neurogenic Inflammation Research Center, Mashhad University of Medical Sciences, Mashhad, Iran.

³Biochemistry of Nutritional Research Center, Mashhad University of Medical Science, Mashhad, Iran.

⁴Department of Physiology, School of Medicine, Mashhad University of Medical Sciences, Mashhad, Iran.

Article Info

Article History:

Received: 7 June 2018
Revised: 4 November 2019
Accepted: 5 January 2019
ePublished: 30 September 2019

Keywords:

-*Ceratonia siliqua*
-Mice
-Spermatozoa
-Apoptosis

ABSTRACT

Background: Certain herbs instigate spermatogenesis; in contrast, some herbs arrest the spermatogenesis cycle. *Ceratonia siliqua* (carob) is a plant with a strong antioxidant property. The aim of this study was to evaluate the effects of carob fruit extract on spermatogenesis, testicular apoptosis, and oxidative stress in adult male mice.

Methods: Forty adult male mice were randomly divided into five groups: control, sham, and carob 1–3. The sham group was injected with normal saline and the carob 1–3 groups were injected with 200, 400, and 800 mg/kg of the carob fruit extract intraperitoneally for 14 days, respectively. At the end of the injection period, spermatogenesis, testicular apoptosis, and oxidative stress were examined.

Results: The sperm parameters increased in the mice that received 200 mg/kg of carob compared to the sham group ($p < 0.05$). There was a significant increase in the weight index of the epididymis in the carob 3 group in comparison to the sham group ($p = 0.01$). The number of positive tunnel cells was not statistically significant between different groups ($p > 0.05$). The level of malondialdehyde decreased in the carob 1 and carob 3 groups, but this reduction was not statistically significant ($p > 0.05$). In addition, the statistical analysis showed a significant difference in the mean superoxide dismutase levels in the carob 2 and carob 3 groups in comparison to the sham group ($p < 0.001$). The statistical analysis showed a significant increase in the mean level of the catalase enzyme in the carob 1 group in comparison to the sham ($p = 0.02$), and carob 2 groups ($p = 0.008$).

Conclusion: The administration of 200 mg of the carob fruit extract for 14 days increased the testicular index as well as sperm parameters and decreased the level of oxidative stress in the testicular tissue of adult mice.

Introduction

The use of herbs to treat infertility has a long history in traditional medicine. Certain plants stimulate spermatogenesis and increase fertility and others reduce or arrest spermatogenesis.¹ *Ceratonia siliqua* is a member of the Fabaceae family, which does not yield any fruit in the first 15 years of its life.² Its brownish colored fruit has a very sweet taste and contains about 14 very hard lenses. This plant grows in certain Asian countries, including China, Malaysia, Turkey, and Iran. It contains 40 percent of carbohydrate, 1 percent of fat, and 4 percent of protein, and comprises high fiber, vitamins E, D, C, B₆, niacin, folic acid, polyphenol, and minerals such as potassium, sodium, calcium, iron, and phosphorus. Studies show that carob improved blood pressure, diabetes,³ and constipation.² In addition, it has anti-cancer,⁴ anti-dyspnea and asthma,² antibacterial,⁵ and strong antioxidant properties.⁶ Studies showed that the addition of 10 and 20

percent carob powder to the diet improved the lipid parameters and histopathology of the heart, liver, and kidney.⁷ Rtibi *et al.* reported the protective effect of the carob carob plant on the stomach of oxidative stress-induced ethanol rats.⁸ Other studies have reported the strong antioxidant as well as cytotoxicity properties of carob extract⁶ and reduced DNA damage by cancer cells.⁴ Carob administration improved colon histopathology, reduced levels of malondialdehyde, and increased levels of antioxidant enzymes in the ulcerative colitis mice model.⁹ In addition, anti-inflammatory¹⁰ and neurotoxic¹¹ properties have been reported for carob. Considering the fact that the plant has shown a positive effect on male fertility in some Iranian cities as well as with the search we conducted, there has not been any research on the effects of the carob fruit on sperm quality and testicular apoptosis. Therefore, the present study aimed to investigate the effects of different doses of the fruit extract

*Corresponding Author: Shabnam Mohammadi, E-mail: mohammadish@mums.ac.ir

©2019 The Authors. This is an open access article and applies the Creative Commons Attribution (CC BY), which permits unrestricted use, distribution and reproduction in any medium, as long as the original authors and source are cited. No permission is required from the authors or the publishers.

on spermatogenesis, testicular apoptosis, and oxidative stress in adult male mice.

Materials and Methods

Animal and ethical issues

After the approval of the Ethics Committee of the Mashhad University of Medical Sciences (code: IR.MUMS.fm.REC.1396.466), 40 adult male BALB/c mice were purchased from an animal house and kept in standard conditions. The mice were randomly divided into five groups (control, sham, and carob 1–3). The control group received no injections. The sham group received normal saline intraperitoneally. The carob 1–3 groups intraperitoneally received 200 mg/kg, 400 mg/kg, and 800 mg/kg of carob for 14 days.¹² Then, the amount of testicular apoptosis, sperm analysis, oxidative stress, and weight organ indexes were evaluated on Day 35 of the experiment.

Evaluation of sperm parameters

After 35 days, the epididymides were placed in normal saline and placed on a CO₂ incubator for 30 minutes. Then, the sperm parameters were examined according to the WHO guidelines.¹³

Testicular apoptosis

After the routine histology passage and testicular tissue cutting, the apoptotic cells of the testis were examined by the Roch Tetal Kit (CAT number: 5301584). The average of the spermatogonial cells, primary spermatocytes, and spermatids in the surface unit were calculated as follows:^{14,15}

$$N_A = \frac{\Sigma \hat{Q}}{\alpha / f \Sigma p} \quad \text{Eq. (1)}$$

In this formula, N_A represents the number of cells per surface unit, $Q\Sigma$ represents the total number of counted cells, α/f represents the surface area of each counting frame, and Σp represents the total number of counted frames.

Measurement of thiol and malondialdehyde Levels

To measure the thiol level, a di-nitrobenzoic acid reagent was used and absorption at 412 nm was investigated by using a spectrophotometer.¹² To measure the level of malondialdehyde, the homogenous tissue of the testis was mixed with chloridric acid and placed in a water bath. After cooling, centrifugation, and absorption at 535 nm, the level was read by the spectrophotometer.¹²

Measurement of the level of catalase and superoxide dismutase enzymes

According to the previous study, the level of catalase and superoxide dismutase enzyme was evaluated.¹²

Calculation of weight index

The following formula was used to detect the weight index of the organs:¹²

$$\text{Weight index} = \frac{\text{Organ weight (g)}}{\text{Body weight (g)}} \times 100 \quad \text{Eq. (2)}$$

Statistical analysis

Data were expressed as percentages and mean \pm standard deviation. The SPSS software, ANOVA test, and Tukey post-test were used for data analysis.

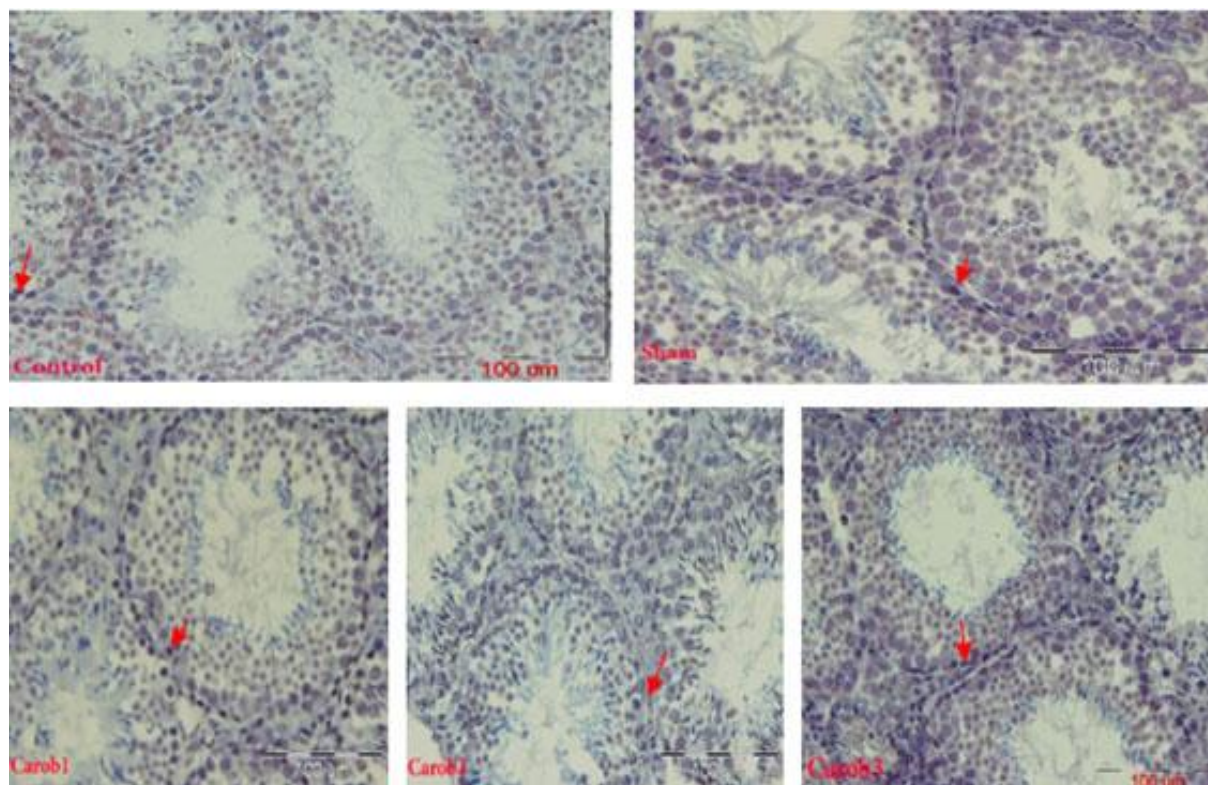


Figure 1. Cross-sectional of seminiferous tubules in different groups by using tunnel staining. Positive tunnel cells are marked with red color.

Table 1. Effect of the extract of carob fruit on the sperm parameters in different groups

Group	Sperm count (million/ml)	Sperm motility (%)	Sperm morphology (%)	Sperm Viability (%)
Control	4.63 ± 0.31	89.75 ± 6.71	84.50 ± 6.82	86.62 ± 4.92
Sham	4.29 ± 0.44	88.37 ± 4.74	83.87 ± 6.37	85.00 ± 4.59
Carob 1	4.36 ± 0.45*	85.75 ± 8.74	89.87 ± 5.30*	85.12 ± 6.46
Carob 2	4.23 ± 0.49#	83.37 ± 5.97	89.25 ± 5.57	84.25 ± 5.06
Carob 3	4.25 ± 0.28#	83.75 ± 6.49	84.50 ± 5.58	84.87 ± 4.12

* (p < 0.05): Significant difference with sham group within same column
 # (p < 0.05): Significant difference with carob1 group within same column

Results

Sperm parameters

Table 1 shows the average sperm count (million per ml). A significant increase was observed in the sperm counts in the carob 1 group in comparison to the sham group

(p=0.03), carob 2 group (p=0.01) and carob 3 group (p=0.01). Statistical analysis showed a significant increase in the normal morphology rate of sperm in the carob1 group in comparison to the sham group (p=0.049).

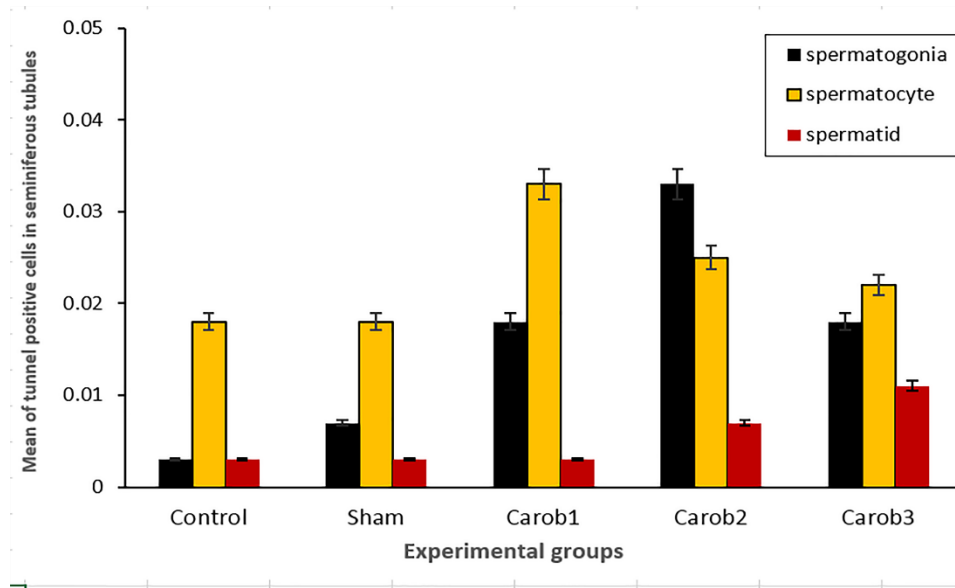


Figure 2. Mean number of positive tunnel cells in the surface unit (N/mm²). The number of positive tunnel cells was not statistically significant between different groups (p>0.05).

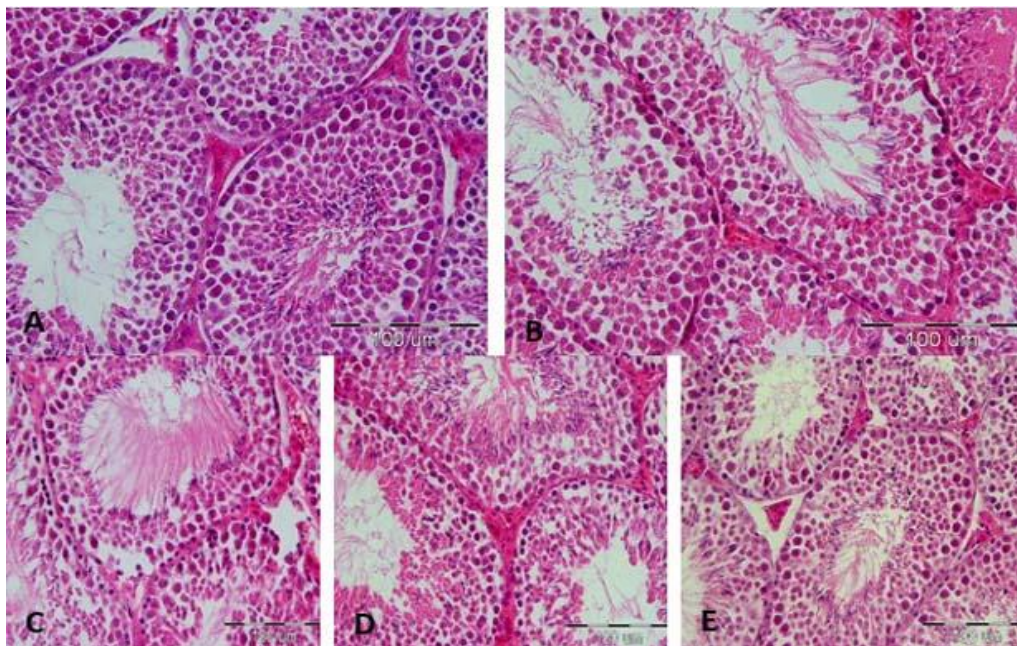


Figure 3. Histopathology of testis with H&E staining.

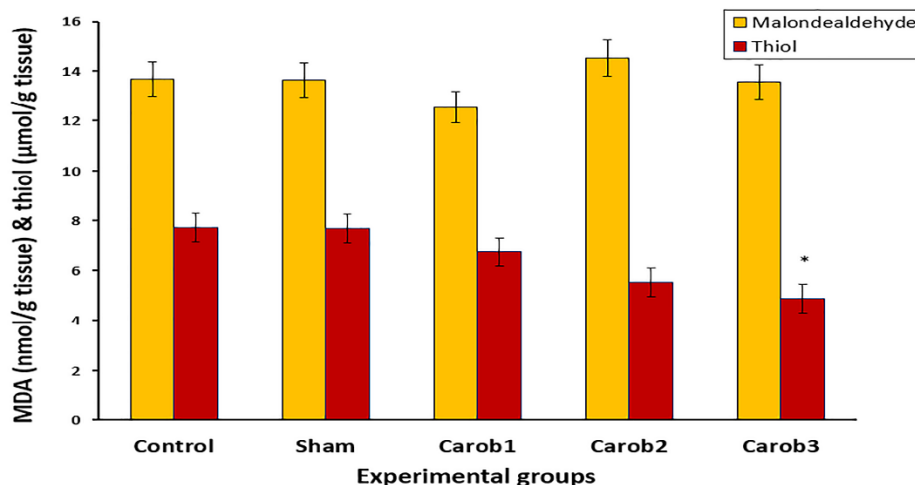


Figure 4. Level of thiol and malondialdehyde in the testicular tissues of different groups. *Significant difference with sham group by ANOVA and Tukey post-hoc test

Testicular apoptosis

The number of positive tunnel cells was not statistically significant between positive different groups ($p > 0.05$). The lowest value of positive tunnel cells was observed in the control group and the highest number of positive tunnel cells was observed in the carob 2 group (Figure 1 and 2).

Testicular histopathology

The histology of seminiferous tubules was normal in the sham group. Histological examination of the carob treated mice was normal and there was not any reduction in the thickness of germinal epithelium, congestion and edema in seminiferous tubules (Figure 3).

Thiol and malondialdehyde levels

Figure 4 shows the levels of thiol and malondialdehyde in the testicular tissue of different groups. The statistical test showed a significant decrease between the mean thiol level in the carob 3 group in comparison to the sham group ($p = 0.02$). The level of malondialdehyde decreased in the carob 1 and carob 3 groups, but this reduction was not statistically significant ($p > 0.05$).

Superoxide dismutase and catalase levels

Table 2 shows the amount of superoxide dismutase and catalase enzymes in different groups in unit/gram. The statistical analysis showed a significant difference in the mean superoxide dismutase levels in the carob 2 and carob 3 groups in comparison to the sham group ($p < 0.001$). Furthermore, there was a significant increase in the mean level of the superoxide dismutase enzyme between the carob 1 group in comparison to the carob 2 group ($p < 0.001$), and the carob 3 group ($p < 0.001$). The statistical analysis showed a significant increase in the mean level of the catalase enzyme in the carob 1 group in comparison to the sham ($p = 0.02$), and carob 2 groups ($p = 0.008$).

Weight index of reproductive organs

The results of the weight index of the reproductive organs

are summarized in Table 3.

Table 2. Levels of superoxide dismutase and catalase enzymes in the testicular tissues of different groups.

Groups	superoxide dismutase enzyme (U/g tissue)	catalase enzyme (U/g tissue)
Control	33.65 ± 3.42#	0.61 ± 0.09
Sham	34.37 ± 4.17	0.59 ± 0.11#
Carob 1	40.53 ± 3.17	0.85 ± 0.07*
Carob 2	19.98 ± 1.69#*	0.51 ± 0.24#
Carob 3	20.06 ± 3.69#*	0.77 ± 0.06

* Significant difference with sham group by ANOVA and Tukey post-hoc test

Significant difference with carob1 group by ANOVA and Tukey post-hoc test

Table 3. Effect of extract of the carob fruit on the weight index of reproductive organs in the different groups.

Groups	Weight index of testis	Weight index of epididymis	Weight index of seminal vesicle	Weight index of prostate
Control	0.29 ± 0.03	0.14 ± 0.04#	0.23 ± 0.06	0.02 ± 0.003
Sham	0.35 ± 0.03	0.15 ± 0.02	0.24 ± 0.08	0.05 ± 0.01
Carob 1	0.37 ± 0.05	0.20 ± 0.03*	0.20 ± 0.07	0.23 ± 0.34
Carob 2	0.36 ± 0.04	0.12 ± 0.05#	0.23 ± 0.07	0.06 ± 0.02
Carob 3	0.35 ± 0.07	0.07 ± 0.02*#	0.24 ± 0.06	0.10 ± 0.03

* ($p < 0.05$): Significant difference with sham group within same column

($p < 0.05$): Significant difference with carob 1 group within same column

A significant increase was observed between the weight index of the epididymis in the carob 3 group ($p = 0.01$) in comparison to the sham group. A significant increase was observed between the weight index of the epididymis in the carob 1 ($p < 0.0001$) group in comparison to the carob 3 group. In addition, there was a significant reduction in the weight index of the epididymis in the carob 2 group in comparison to the carob 1 group ($p = 0.02$).

Discussion

The results of this study showed that the sperm parameters were increased in the mice that received 200 mg/kg of carob compared to the sham group. The number of positive tunnel cells was not statistically significant between different groups. A significant reduction was observed in the level of thiol in the mice administered with 800 mg/kg of carob. A significant increase in the mean level of antioxidant enzymes and the testicular weight index in the mice received 200 mg/kg of carob. The epididymal weight index increased in the carob 1 group in comparison to the sham group. Mokhtari *et al.* investigated the effect of the hydroalcoholic extract of the carob seed on pituitary-testicular hormones and spermatogenesis in rats. Their results showed that the carob extract increased the testosterone, dihydrotestosterone, and LH levels in the groups receiving a dose of 150–300 mg/kg of carob, but the FSH level was not significantly different.¹⁶ In the present study, the administration of a 200 mg/kg carob increased the number and the percentage of normal sperm morphology, thus indicating that the antioxidant dosage and treatment duration were very important.¹⁷

Other researchers reported that carob caused apoptosis and the activation of caspase 3 within 24 hours after use in a culture of cancer cells.¹⁸ The results of the present study also showed that carob-induced apoptosis in a testicular tissue, although it was not statistically significant.

Rtibi *et al.* studied the protective effect of carob on the stomach of oxidative stress-induced ethanol rats. They concluded that the carob extract had protective effects on the gastric mucosal tissue and improved the antioxidant activity of the catalase, glutathione peroxidase, and superoxide dismutase enzymes.⁸ The researchers reported that administration with carob improved colon histopathology and reduced the levels of malondialdehyde as well as increased the levels of glutathione peroxidase, superoxide dismutase, and catalase in ulcerative colitis models.⁹ Ahmed studied the protective effects of 100 and 200 mg/kg carob on the kidneys of mice treated with cisplatin, an anticancer drug. Their results showed that the administration of carob increased the level of antioxidant enzymes, such as superoxide dismutase, catalase, and glutathione peroxidase.¹⁹ In a study by Suzeah *et al.*, the protective effects of carob extract on the livers and kidneys of rats treated with carbon tetrachloride (CCl₄) were investigated. Based on the results of this study, carob powder can be used as an antioxidant to reduce MDA and inhibit CCl₄ production as well as reduce free radicals.²⁰ In line with these studies, in the present study, the extract of the carob fruit in a specific dose (200 mg/kg) increased the levels of catalase and superoxide dismutase enzymes. The testicular tissue changes in healthy mice are physiologic but not pathologic. However, in present study, oxidative stress, testicular dysfunction and apoptosis in testicular tissues of healthy animals were not significant. Only in the thiol and superoxide dismutase

levels in the Carob 3 group there was a significant difference with the sham group. This suggests that the dose and duration of use are important in the antioxidant administration and antioxidants are a double-edged sword. The administration of inappropriate dose or unsuitable treatment time even leads to reversible effects. In our previous study¹² the toxicity model of testis was induced with busulfan in mice and obvious testicular tissue dysfunction and change can be seen. In healthy mice the changes in oxidative stress and testicular dysfunction was not major.

The purpose of this study was to evaluate the positive or negative effects of different doses of the carob extract in healthy mice. At the same time, histopathology of the liver and kidneys of the rats as well as the level of liver enzymes and urea and creatinine were also investigated (data are not shown). No liver and kidney toxicity was observed for carob extract. Carob extract contains vitamins E, D, C, B6, niacin, folic acid, polyphenol, and minerals such as potassium, sodium, calcium, iron, and phosphorus. Studies show that carob has strong antioxidant property.⁶ It seems that carob has an effect on malondialdehyde levels and the body's antioxidant system, which leads to changes in the level of oxidative stress.

It seems that the mechanism of possible effect of carob fruit extract on testicular apoptosis through effect on genes involved in apoptosis. In addition, its effect on malondialdehyde levels and the body's antioxidant system leads to changes in the level of oxidative stress. In this study, it was better to investigate the expression of the apoptosis genes, which is recommended for future studies. In addition, the effects of other parts of the plant, such as leaves and shells, and the effects of its alcoholic extract are recommended.

Conclusion

The administration of 200 mg of the carob fruit extract for 14 days increased the testicular index as well as sperm parameters and decreased the level of oxidative stress in the testicular tissue of adult mice.

Acknowledgments

This article is derived from the MSc thesis in Anatomy Sciences (code 941613) that has been funded by the Vice-Chancellor of Research at Mashhad University of Medical Sciences. We thank Fatemeh Tajik and Azam Amini for their skilled assistance.

Conflict of interests

The authors claim that there is no conflict of interest.

References

1. D'Cruz SC, Vaithinathan S, Jubendradass R, Mathur PP. Effects of plants and plant products on the testis. *Asian J Androl.* 2010;12(4):468-79. doi: 10.1038/aja.2010.43

2. Battle I, Tous J. Carob tree *Ceratonia siliqua*. Italy: International Plant Genetic Resources Institute; 2009. p. 26-30.
3. Mokhtary M, Sharifi A, Shahamir-Tabatabaee M. The effect of carob on liver function test in diabetic male rat. *J Shahrekord Univ Med Sci.* 2013;15(3):40-7.
4. Klenow S, Gleis M, Haber B, Owen R, Pool-Zobel BL. Carob fibre compounds modulate parameters of cell growth differently in human HT29 colon adenocarcinoma cells than in LT97 colon adenoma cells. *Food Chem Toxicol.* 2008;46(4):1389-97. doi:10.1016/j.fct.2007.09.003
5. Meziani S, Oomah BD, Zaidi F, Simon-Levert A, Bertrand C, Zaidi-Yahiaoui R. Antibacterial activity of carob (*Ceratonia siliqua* L.) extracts against phytopathogenic bacteria *Pectobacterium atrosepticum*. *Microb Pathog.* 2015;(78):95-102. doi:10.1016/j.micpath.2014.12.001
6. Seczyk L, Swieca M, Gawlik-Dziki U. Effect of carob (*Ceratonia siliqua* L.) flour on the antioxidant potential, nutritional quality, and sensory characteristics of fortified durum wheat pasta. *Food Chem.* 2016;194:637-42. doi:10.1016/j.foodchem.2015.08.086
7. Hassanein KMA, Youssef MKE, Ali HM, El-Manfaloty MM. The influence of carob powder on lipid profile and histopathology of some organs in rats. *Comp Clin Path.* 2015;24(6):1509-13. doi:10.1007/s00580-015-2108-x
8. Rtibi K, Jabri MA, Selmi S, Souli A, Sebai H, El-Benna J, et al. Gastroprotective effect of carob (*Ceratonia siliqua* L.) against ethanol-induced oxidative stress in rat. *BMC Complement Altern Med.* 2015;15(1):292. doi:10.1186/s12906-015-0819-9
9. Rtibi K, Selmi S, Jabri MA, EL-Benna J, Amri M, Marzouki L, et al. Protective effect of *Ceratonia siliqua* L. against a dextran sulfate sodium-induced alterations in liver and kidney in rat. *J Med Food.* 2016;19(9):882-9. doi:10.1089/jmf.2016.0020
10. Aboura I, Nani A, Belarbi M, Murtaza B, Fluckiger A, Dumont A, et al. Protective effects of polyphenol-rich infusions from carob (*Ceratonia siliqua*) leaves and cladodes of *Opuntia ficus-indica* against inflammation associated with diet-induced obesity and DSS-induced colitis in Swiss mice. *Biomed Pharmacother.* 2017;96:1022-35. doi:10.1016/j.biopha.2017.11.125
11. IH El-Sayyad H, Elkholy WME, Hamed WAE. Promising role of Carob (*Ceratonia siliqua* L.) phytochemical components against neurotoxicity induced by monosodium glutamate. *Glob J Zool.* 2017;2(1):24-32. doi:10.17352/gjz.000008
12. Vafaei A, Mohammadi S, Fazel A, Soukhtanloo M, Mohammadi pour A, Beheshti F. Effects of Carob (*Ceratonia siliqua*) on sperm quality, testicular structure, testosterone level and oxidative stress in busulfan-induced infertile mice. *Pharm Sci.* 2018;24(2); 104-11. doi:10.15171/ps.2018.16
13. Mohammadi Sh, Golamin M, Mohammadi M, Mansouri A, Mahmoodian R, Attari S, et al. Down-regulation of CatSper 1 and CatSper 2 genes by lead and mercury. *Environ Toxicol Pharmacol.* 2018;59:82-6. doi:10.1016/j.etap.2018.03.007
14. Mohammadi S, Khakbaz M, Shoraka M, Vakil S, Moghimian M, Mohammadzadeh F, et al. Effects of different doses of manganese on lead poisoning in the kidney of adult male mice. *Koomesh.* 2016;18(1):203-10.
15. Mohammadi S, Pakrouh Z, Teimouri M, Hagi pour S, Karimi M, Mohammadi M, et al. Effects of drug substance crystal (methamphetamine) on histopathology and biochemical parameters of kidney in adult male mice. *Sci J Kurdistan Univ Med Sci.* 2015;20(4):83-90.
16. Mokhtary M, Sharifi E, Azadian S. The effect of hydro alcoholic extract of *Ceratonia siliqua* L seeds on pituitary-testis hormones and spermatogenesis in rat. *Adv. Environ. Biol.* 2012;6(10):2778-83.
17. Mohammadi S, Safari F, Seyedi Z, Seyed Hosseini E, Karimi F, Mohammadi M, et al. The Effect of different doses of N-acetyl cysteine on biochemical and histopathological parameters in kidney of formalin-treated. *J Kerman Univ Med Sci.* 2016;3(5):607-17.
18. Corsi L, Avallone R, Cosenza F, Farina F, Baraldi C, Baraldi M. Antiproliferative effects of *Ceratonia siliqua* L. on mouse hepatocellular carcinoma cell line. *Fitoterapia.* 2002;73(7-8):674-68. doi:10.1016/s0367-326x(02)00227-7
19. Ahmed MM. Biochemical studies on nephroprotective effect of carob (*Ceratonia siliqua* L.) growing in Egypt. *Nat Sci Sleep.* 2010;8(3):41-7
20. Suzek H, Celik I, Dogan A. Nephroprotective Hepatoprotective Potential and Antioxidant Role of Carob Pods (*Ceratonia siliqua* L.) against Carbon Tetrachloride-induced Toxicity in Rats. *Indian J Pharm Educ,* 2017;51(2):312-20. doi:10.5530/ijpe r.51.2.37