



## Effects of *Polygonum avicular* Extract on Histological Changes of Mouse Seminiferous Tubules after Electromagnetic Field Exposure

Sara Ansari<sup>1</sup>, Peiman Brouki Milan<sup>2</sup>, Daryoush Mohammadnejad<sup>3</sup>, Abbas Delazar<sup>4</sup>, Motahareh Mortazavi<sup>1</sup>, Amaneh Mohammadi Roushandeh<sup>5\*</sup>

<sup>1</sup>Anatomical Sciences Department, Medicine faculty, Hamadan University of Medical Sciences, Hamadan, Iran.

<sup>2</sup>Tissue engineering and cell Therapy Department, school of advanced technologies in medicine, Tehran university of medical science, Tehran, Iran.

<sup>3</sup>Anatomical Sciences Department, Medicine faculty, Medical University of Tabriz, Tabriz, Iran.

<sup>4</sup>Pharmacognosy Department, Faculty of Pharmacy, Tabriz University of Medical Sciences, Tabriz, Iran.

<sup>5</sup>Research center for Moleculare Medicine, Medicine faculty, Hamadan University of Medical Sciences, Hamadan, Iran.

### ARTICLE INFO

#### Article Type:

Original Research

#### Article History:

Received: 20 February 2014

Accepted: 15 March 2014

#### Keywords:

Electromagnetic fields

*Polygonum avicular*

Testis

Seminiferous tubules

### ABSTRACT

**Background:** Electromagnetic field (EMF) has harmful effects on different tissues specially testis through different mechanisms such as increase free radicals. Therefore, application of antioxidants may reduce these abnormalities. *Polygonum aviculare* extract (PAe) as an herbal plant has antioxidant activities. Therefore, in the present study, its protective property against EMF was investigated in testis. **Methods:** 6 weeks old male Balb/c mice were divided to control (without EMF exposure), EMF (exposed to 3 mT EMF for 8 weeks), EMF+PAe (received 50 mg/kg PAe and 3mT EMF for 8 weeks) and PAe (received only 50 mg/kg PAe for 8 weeks) groups. After 8 weeks the animals were sacrificed, the testes were dissected out and fixed, and then stained with hematoxylin and eosin (H & E). The sections were subjected to morphometric and histological analysis. **Results:** Morphological studies showed that germinal epithelium of testes was negatively affected by EMF and the PAe reduced the harmful effects. **Conclusion:** As expected, EMF waves have destructive effects on testis morphology via producing free radicals that may cause male infertility. The herbal medicines such as *polygonum aviculare* extract have antioxidant activity and can reduce the harmful effects of EMF.

### Introduction

An electromagnetic field is a physical field produced by electrically charged objects and the living organisms such as humans beings are exposed to it, unavoidably. Recently, several studies evaluated the effects of electromagnetic fields on human health, histologically and physically. Also, The WHO's International Agency for Research on Cancer has published a review of the evidence on health risks of electromagnetic fields (EMFs), concluding that there was limited evidence that cell phone users might be at increased risk of glioma and acoustic neuroma, and that there was inadequate evidence of any other health risks posed by EMF. In order to discussion of the EMF action's mechanism on cells several hypothesis have been suggested. The most plausible target for EMFs is the plasma membrane and transmembrane proteins that lead to a chain of chemical reactions called lipid peroxidation, which in turn cause to reduce the membrane fluidity and the activity of membrane enzymes and ion channels, and so the inhibition of normal cellular mechanisms required for fertilization. Furthermore, the involvement of lipid peroxidation,

free radical formation and so induction of oxidative stress has proofed for EMF effects on the live cells. Exposure to environmental EMF enhances the generation of reactive oxygen species (ROS) and thus causes destroyer effects on different cellular organelles such as the cellular nucleus and DNA (Agarwal and Prabakaran 2005). Similar to ionizing radiations, high levels of EMF produce oxygen-derived free radicals that have destructive effects on cells and induce oxidative stress (OS). Reactive oxygen species (ROS) can peroxidize polyunsaturated fatty acids (PUFA) of sperm cell membrane and proteins, and damage DNA in cells.<sup>1</sup> Although, excessive levels of ROS have harmful effects on sperms and contribute to men infertility, these potentially deleterious molecules are necessary to sperm capacitation. Sperms generate controlled-amount of ROS during mammalian sperm capacitation to promote sperm motility and capability to undergo acrosomal reaction.<sup>2</sup> Epididymis and seminal plasma (SP) contains antioxidants to scavenge ROS and protect sperms against OS. These natural antioxidants include enzymes catalase, superoxide

\*Corresponding Author: Amaneh Mohammadi Roushandeh, Research center for Moleculare Medicine, Medicine faculty, Hamadan University of medical sciences, Hamadan, Iran. Tel: +98 9143078216, Fax: +98 811 8380208, E-mail: [a.mohammadiroshandeh@umsha.ac.ir](mailto:a.mohammadiroshandeh@umsha.ac.ir)

dismutase (SOD), glutathione peroxidase (GPX), glutathione reductase (GPR) and high concentration of ascorbic acid and uric acid and thiol groups and  $Zn^{2+}$  ion. Since, sperms contain low concentration of antioxidants, excessive amounts of ROS or low activities level of native antioxidants would result in cellular damage. Thus, antioxidants can be supplemented as a therapeutic agent. Today, different natural antioxidants are isolated from plants; used to treat male infertility.<sup>3</sup>

*Polygonum aviculare* L. (Polygonaceae) is an astringent, coagulant, diuretic herb and is reputed to treat wounds and kidney stones. This plant belongs to *Polygonum* L. (knotweed) and is an annual weed of worldwide distribution that is frequently found in Azarbaijan province (Northwestern of Iran). It is shown that its extract has a high content of phenolics compounds and flavonoids.<sup>4,5</sup> It is reported that phenolic compounds possess antioxidant activities and can scavenge free radicals. Therefore, since WHO recommends application of traditional drugs in medical health service system, the objective of this study was to evaluate antioxidant activity of *Polygonum aviculare* extract on morphology of testis seminiferous tubules in mouse exposed to EMF.

## Materials and Methods

### Animals

Male Balb/c mice (8 weeks) were obtained from animal house of the Tabriz University of Medical Sciences, Tabriz, Iran. The laboratory was maintained on a 12/12-hr light/dark cycle. Animal experiments were approved by the ethical committee of Tabriz medical university and performed in accordance with the guidelines.

### Grouping

Mice were divided into 4 groups, control (without EMF exposure), EMF (exposed to 3 mT EMF for 8 weeks), EMF+PAe (received 50 mg/kg PAe and 3mT EMF for 8 weeks) and PAe (received only 50 mg/kg PAe for 8 weeks) groups. The control group was maintained in EMF generator machine while it was off for 8 weeks. The EMF group was exposed to 3mT EMF for 4 hours/day and 5 days/week; 8 weeks. The third group was exposed to EMF while treated with 50 mg/kg the herbal extract. Animals in last group treated daily with 50 mg/kg of extract for 8 weeks. It is noted that the *polygonum aviculare* solved in DMSO but it was in very low volume, therefore the solvent group was not necessary.

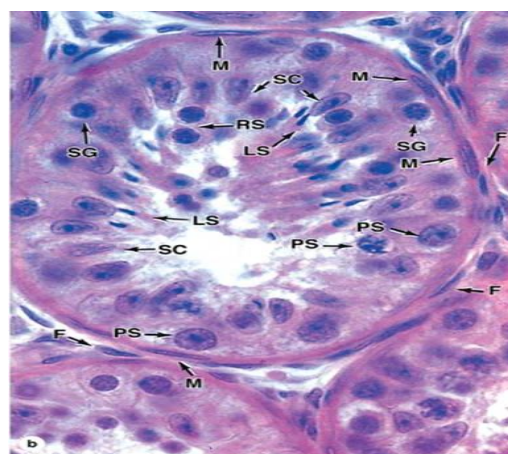
### *Polygonum avicular* extract method

*Polygonum avicular* was collected from Oscow Mountains in (Azarbaijan province of Iran) in summer of 2008. Voucher specimens for this collection (AD2009-1892) have been deposited in the Herbarium of the Faculty of Pharmacy; Tabriz, Iran and Prof. A. Delazar determined the plant. The extraction method

was maceration. The plant naturally dried in a suitable laboratory space and away from sunlight. The dried parts were ground into a fine powder by a mechanical mill. The dried, powdered plants (100g) were successively extracted with a Soxhlet apparatus, using methanol in 5 hours. After extraction, fractions were concentrated to dryness at 50°C on a rotary evaporator under reduced pressure. The final extract was stored in a refrigerator below 0 °C.

### Histological study

After 8 weeks the mice were sacrificed by cervical dislocation and the testis immersed in Bouin's fixative for morphological and morphometrical study of seminiferous tubules. After fixation and tissue processing, the 5µ sections were stained with Hematoxylin and Eosin. Germinal epithelium, diameter and interstitial tissues of seminiferous tubules were studied with light microscope. Histological examination on testicular morphology was performed under 40× magnifications in five fields for each slide. Germinal epithelium cells were detected according to routine histological books and guide with Dr Mohammadnejad Ph.D in Histology and embryology in Tabriz Medical University. Primary spermatocytes are the largest spermatogenic cells and are usually abundant at all levels between the basement membrane and the lumen (Figure 1).



**Figure 1.** In the cross sections of seminiferous tubules most of the associated cell types can be seen. Outside the tubules are myoid cells (M) and fibroblasts (F). Primary spermatocytes are the largest spermatogenic cells and are usually abundant at all levels between the basement membrane and the lumen. X750. H&E.

### Data analysis

The data were analyzed with SPSS software (version 16.0) and ANOVA. Differences were considered statistically significant at  $P < 0.05$ .

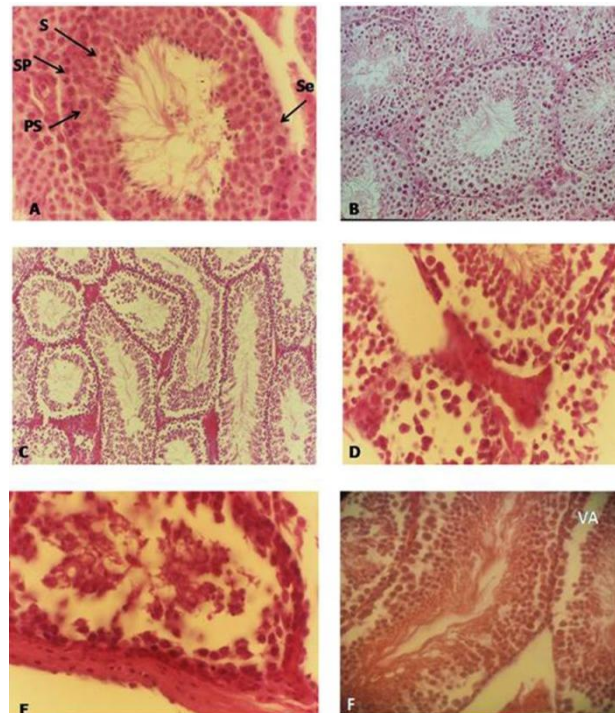
## Results

### Histological studies

The results obtained in light microscope indicated thick

germinal epithelium and active spermatogenesis in seminiferous tubules in control group. Germinal epithelium appeared normal and spermatogenic cells were located adjacent to the basal lamina and Sertoli cells were found in the lumen of the seminiferous

tubules and both of them were distinguishable and countable (Figure 2 A). In *Polygonum aviculare*-treated group with 50 mg/kg of the extract did not observed changes in histological appearance and organization of seminiferous tubules (Figure 2 B).



**Figure 2.** (A) Light photomicrograph of seminiferous tubules in the control group showed normal appearance of the germinal epithelium and regular organization of Seminiferous tubules were organized, regularly (arrows), spermatogonia (SP), Sertoli cells (Se), primary spermatocytes (PS), spermatids (S) and Leydig cells (arrows) (H&E staining, Mag. 400x).

(B) Light photomicrograph of seminiferous tubules in the *polygonum aviculare*-treated group. Germinal epithelium was normal (H&E staining, Mag. X200).

(C-E) Light photomicrograph of seminiferous tubules in EMF-treated group. Reduced height of germinal epithelium and disorganization of the tubules were noticeable. An increase in interstitial tissue was observed. Primary spermatocytes were located distance from basal lamina. Vacuoles were seen within germinal epithelium of seminiferous tubules (H&E staining Mag. 100 xs (C) Mag. 400x (D&E).

(F) Light photomicrograph of seminiferous tubules in EMF-exposed plus *polygonum aviculare* extract-treated. Notice the height of germinal epithelium and vacuoles (Va). Germinal epithelium improved compare to EMF group. (H&E staining) Mag. 200 x).

Seminiferous tubules appeared Irregular shape and wide space between them in EMF-treated group. In addition, abnormality in distribution and position of germ cells within seminiferous tubules were observed. Leydig cell hypoplasia and thinning of germinal epithelium were seen. Disorganization of seminiferous tubules and reduction in height of germinal epithelium were distinguished (Figure 2 C - E).

Germinal epithelium of the seminiferous tubules was normal in group exposed to EMF in concurrent with 50mg/kg body weight *polygonum aviculare* compared to EMF-exposed group. Also different spermatogenic stages were observed almost in all tubules. However, vacuoles were distinguishable in some tubules. (Figure 2 F)

### Morphometric findings

20 tubules in each group were selected randomly, small and large diameter of the tubules were measured and reported as mean. Our results showed that EMF-

exposed group with a mean of  $30.11 \pm 5.84$  had a significant decrease compared to other groups ( $p < 0.01$ ). In addition, EMF-exposed plus *polygonum aviculare* treated group ( $46.2 \pm 7.69$ ) showed increase in tubules diameter significantly compared to EMF-exposed group ( $P < 0.01$ ), while control and *polygonum aviculare*-treated groups ( $49.66 \pm 2.24$  and  $49.22 \pm 5.43$  respectively) had maximum diameter of tubules without significant differences between them.

### Germinal epithelium cells

Sertoli cells were counted in 20 randomly selected seminiferous tubules in each group. The mean number of the cells in each group were  $9.42 \pm 2.12$  in control,  $8.99 \pm 1.5$  in *polygonum aviculare* extract-treated group,  $11.76 \pm 1.01$  in EMF-exposed group and  $11.03 \pm 1.39$  in EMF-exposed plus *polygonum aviculare* extract-treated group. Our findings indicated significant increase in Sertoli cells number in EMF-exposed group compared to control group ( $p < 0.05$ ). However, a



difference between EMF-exposed group and EMF-exposed plus *polygonum aviculare* extract-treated group was not significant.

Number of spermatogonia cells was  $16.33 \pm 2.18$  in control,  $16.47 \pm 1.86$  in *polygonum aviculare*-treated,  $8.76 \pm 2.01$  in EMF-exposed and group was  $9.03 \pm 0.45$  EMF-exposed plus *polygonum aviculare* extract-

treated group. As it is shown in Table 1 Spermatogonia cells were significantly decreased in EMF-exposed group compared to control ( $p < 0.05$ ). The number of the cells in EMF-exposed plus *polygonum aviculare* extract-treated group was increased compared to EMF-exposed group but was not significant (Table 1).

**Table 1.** Mean number of germinal epithelium of seminiferous tubules such as spermatogonia and sertoli cells in different control, EMF, POLY and EMF+ POLY groups ( $P < 0.05$ ).

	Control	EMF	EMF + POLY	POLY
Sertoli cell number	$9.42 \pm 2.12$	$11.76 \pm 1.01$	$11.03 \pm 1.39$	$8.99 \pm 1.58$
Spermatogonia	$16.33 \pm 2.18$	$8.76 \pm 2.01$	$9.03 \pm 0.45$	$16.47 \pm 1.86$

## Discussion

Present study was investigated protective effect of *Polygonum aviculare* extract against EMFs in testis tissue. Investigation revealed that in men who have abnormal spermogram taking vitamin and antioxidant supplements, might improve sperm parameters like motility, count, morphology, and percentage of live sperms. Therefore, herbal medications which contain antioxidants can be used in infertility treatment.<sup>6,7</sup>

Infertile couples and consequential issues of infertility in addition to chemical medication side effects, environmental factors and costly surgery, lead to increasing consumption of herbal medications among individuals are infertile.<sup>8</sup>

Sperm parameters analysis in our previous study showed that motility significantly decreased in mice exposed to EMF and percentage of abnormal sperms increased as well.<sup>9</sup> Similar to ionizing radiations, EMFs have a high level of energy that creates free radicals. Increased levels of oxygen free radicals have a destructive effect on sperms and are a prevalent cause of male infertility. ROS have beneficial and detrimental effects on sperm functions depending on the nature and concentration of ROS.<sup>10</sup>

Gomez et al. showed that levels of ROS produced by sperm were negatively correlated with the quality of sperm in the semen.<sup>10</sup> Agarwal et al. found that cell phone use decreased semen quality in 361 men by reducing sperm count, motility, viability, and normal morphology. They also determined that decrease in sperm parameters was dependent on duration of daily exposure to cell phones and independent of the initial semen quality.<sup>1</sup>

Ollero et al. showed that ROS-induced damage of membrane phospholipids and DNA in human sperm has been implicated in pathogenesis of male infertility. The high levels of ROS production and DNA damage observed in immature sperm with abnormal head morphology and cytoplasmic retention and lowest in mature sperm. In addition, the study revealed significant differences in ROS production, lipid content and chromatin structure in ejaculation human sperm and marked changes in these parameters during the

process of sperm maturation.<sup>11</sup>

Our previous studies indicated that EMF could affect antioxidants gene expression such as lipocalin 2 and methalothionine 1, 2 in liver and testis tissues. Our findings showed that EMF down regulates the expression of lipocalin 2, a cytoprotective molecule, in testis tissue. Lcn 2 down regulation can be one of the mechanisms that contribute to the decreased fertility observed after exposure to EMF. Surprisingly, lipocalin 2 expression increased in liver tissue after EMF exposure. The up-regulation might be a compensatory response that involves cell defense pathways and protective effects against ROS. However, further and complementary studies are required in this regards.

MT1 and MT2 genes were down-regulated significantly in testis tissue in mice exposed to EMF both in mRNA and protein level. Taken together it is suggested that the mechanism acts on cells exposed to EMF is antioxidants genes expression profile.<sup>12,14</sup>

Agarwal et al showed that sperm motility in men with oligoteratospermia was increased 40% after taking Speman herbal medication which contains 8 different herbal extracts of *Orchis mascula*, *Lactuca scariola*, *Hygrophila spinosa*, *Mucuna pruriens*, *Parmelia perlata*, *Argyrea speciosa*, *Tribulus terrestris* , *Leptadenia reticulata*.<sup>1</sup>

Gonzales et al. study showed that sperm motility was significantly increased in healthy men who received tablets of *Lepidium meyenii* or Maca (1500 or 3000 mg/day) for 4 months. *Lepidium* contain phenolic components and has antioxidant activity.<sup>15</sup> Many studies concerning the effects of plants on mouse sperm has also been reported. Park's research showed that in rats that treated with *Panax ginseng* plant 56 days of oral gavage resulted in the increase in sperm motility.<sup>16</sup> Experimental data show that anatomical defects of spermatozoa are accompanied by sperm inactivation. Many clinical reports show that sperm morphological abnormalities associated with infertility.<sup>17,18</sup>

Our previous results showed that 26% of sperms were morphologically normal in EMF mice. In groups treated with herbal extract, EMF and *Polygonum*

aviculare mice had a higher proportion of morphologically normal sperm compared to EMF mice.<sup>9</sup>

Al-Qarawi in 2005 showed that 30 days of oral gavage of *Ruta chalepensis* plant increased morphology parameters in normal rats.<sup>19</sup> According to Shukla in 2007, in men who were under psychological stress, taking *Mucuna pruriens* plants increase the morphological parameters over 3 months.<sup>20</sup>

Microscopic study of testis in our study showed that seminiferous tubules had irregular shapes in mice exposed to 3mT EMF. In addition, distance between seminiferous tubules was increased. Normal distribution and arrangements of germinal cells were affected. Leydig cell hypoplasia and thinning of germinal epithelium was seen. After herbal extract treatment, the space between seminiferous tubules reduced and germinal epithelium organization improved. Apparently, disorganization of seminiferous tubules is result of the emergence of edema and an increased permeability of cell membranes due to EMF effect on membrane.

It seems that reduction in spermatogonia number is due to mitotic division problems. Leydig cells are the only somatic cells of seminiferous tubules are in close association with the germinal cells, and provide appropriate environment and support for proliferation spermatogonia. Thus, any change in these cells may lead to infertility.

Our previous paper indicated EMF impact on sperm parameters not to histological issue. In present study sertoli cells and spermatogonia number are not significant between EMF and EMF plus polygonum aviculare group, while, according to our previous study spermatozoa number are significant between two groups. It is suggested that some pathological changes occurred in the spermatogonia and sertoli cells that is not detected and results to failure in spermatogenesis.<sup>9</sup> However more investigation requires improving our knowledge about mechanisms of the herbs on reproduction system.

## Conclusion

Our findings proved that polygonum avicular could improve histological changes after EMF exposure. But for application on human needs more studies.

## Acknowledgement

Authors are thankful to Research Deputy of Tabriz medicine faculty for funding support of project No: 89/20.

## References

- Agarwal A, Nallella KP, Allamaneni SS, Said TM. Role of antioxidants in treatment of male infertility: an overview of the literature. *Reprod Biomed online* 2004;8:616-27.
- De Lamirande E, Jiang H, Zini A, Kodama H, Gagnon C. Reactive oxygen species and sperm

physiology. *Rev Reprod* 1997;2:48-54.

- Marberger M. Oxidative stress and epididymal sperm transport, motility and morphological defects. *Eur J Obstet Gynecol Reprod Biol* 2009;144:S199-S203.
- Hsu C. Antioxidant activity of extract from *Polygonum aviculare* L. *Biol Res* 2006;39:281.
- Chon SU, Heo BG, Park YS, Cho JY, Gorinstein S. Characteristics of the leaf parts of some traditional Korean salad plants used for food. *J Sci Food Agric* 2008;88:1963-8.
- Miciński P, Pawlicki K, Wielgus E, Bochenek M, Gogol P, Ficek B. Total reactive antioxidant potential and DNA fragmentation index as fertility sperm parameters. *Reprod Biol* 2011;11:135-44.
- Flower A, Liu J, Chen S, Lewith G, Little P. Chinese herbal medicine for endometriosis (Review). *Cochrane Database Syst Rev* 2009;3.
- Park JJ, Kang M, Shin S, Choi E, Kwon S, Wee H, et al. Unexplained infertility treated with acupuncture and herbal medicine in Korea. *J Altern Complement Med* 2010;16:193-8.
- Milan P, Nejad D, Ghanbari A, Rad I, Nasrabadi H, Roudkenar M, et al. Effects of polygonum aviculare extract on sperm parameters after EMF exposure in mouse. *Pak J Biol Sci* 2011;14:720-4.
- Gomez E, Irvine D, Aitken R. Evaluation of a spectrophotometric assay for the measurement of malondialdehyde and 4-hydroxy-alkenals in human spermatozoa: Relationships with semen quality and sperm function. *Int J Androl* 1998;21:81-94.
- Ollero M, Gil-Guzman E, Lopez MC, Sharma RK, Agarwal A, Larson K, et al. Characterization of subsets of human spermatozoa at different stages of maturation: implications in the diagnosis and treatment of male infertility. *Hum Reprod* 2001;16:1912-21.
- Ebrahimi-Kalan A, Roudkenar MH, Halabian R, Milan PB, Zarrintan A, Roushandeh AM. Down-Regulation of Metallothionein 1 and 2 after Exposure to Electromagnetic Field in Mouse Testis. *Iran Biomed J* 2011;15:151.
- Mohammadi Roushandeh A, Halabian R, Soleymannirad J, Sadeghzadeh OB, Mahdipour A, Nourani MR, et al. High Frequency Electromagnetic Field Induces Lipocalin 2 Expression in Mouse Liver. *Iran J Basic Med Sci* 2010;IJBS 13:139-145.
- Mohammadi Roushandeh A, Halabian R, Mozafari P, Soleimani Rad J, Sadeghzadeh Oskouei B, Samadi Kuchaksaraei A, et al. Down-Regulation of lipocalin 2 expression in mouse testis after exposure to electromagnetic field. *Iran J Med Sci* 2009;34:265-70.
- Geldziler BD, Marcello MR, Shakes DC, Singson A. The genetics and cell biology of fertilization. *Methods Cell Biol* 2011;106:343.
- Gonzales GF, Cordova A, Gonzales C, Chung A, Vega K, Villena A. *Lepidium meyenii* (Maca)

- improved semen parameters in adult men. *Asian J Androl* 2001;3:301-4.
17. Park WS, Shin DY, Kim DR, Yang WM, Chang MS, Park SK. Korean ginseng induces spermatogenesis in rats through the activation of cAMP-responsive element modulator (CREM). *Fertil Steril* 2007;88:1000-2.
18. Gu L, Chen Z, Lu W, Xu J, Li M, Chen Z. Effects of abnormal structure of sperm chromatin on the outcome of in vitro fertilization and embryo transfer. *Zhonghua Yi Xue Yi Chuan Xue Za Zhi* 2011;28:156.
19. Al-Qarawi AA. Stimulatory effect of the aqueous extract of *Ruta chalepensis* on the sex organs and hormones of male rats. *J Appl Res* 2005;5:206-11.
20. Shukla KK, Mahdi AA, Ahmad MK, Jaiswar SP, Shankwar SN, Tiwari SC. *Mucuna pruriens* reduces stress and improves the quality of semen in infertile men. *Evid Based Complement Alternat Med* 2010;7:137-44.